



UNIVERSITÀ  
DEGLI STUDI  
DI TORINO



# Clinical case: 2 stents are better than 1?

Dott. Fabrizio D'Ascenzo

Division of Cardiology, Department of Internal  
Medicine

[fabrizio.dascenzo@gmail.com](mailto:fabrizio.dascenzo@gmail.com)

# CONFLICT OF INTERESTS

Abbott  
Boston  
Chiesi  
Cros nt  
Medtronic

# CLINICAL CASE PRESENTATION

Woman 67 years old

CVRFs:

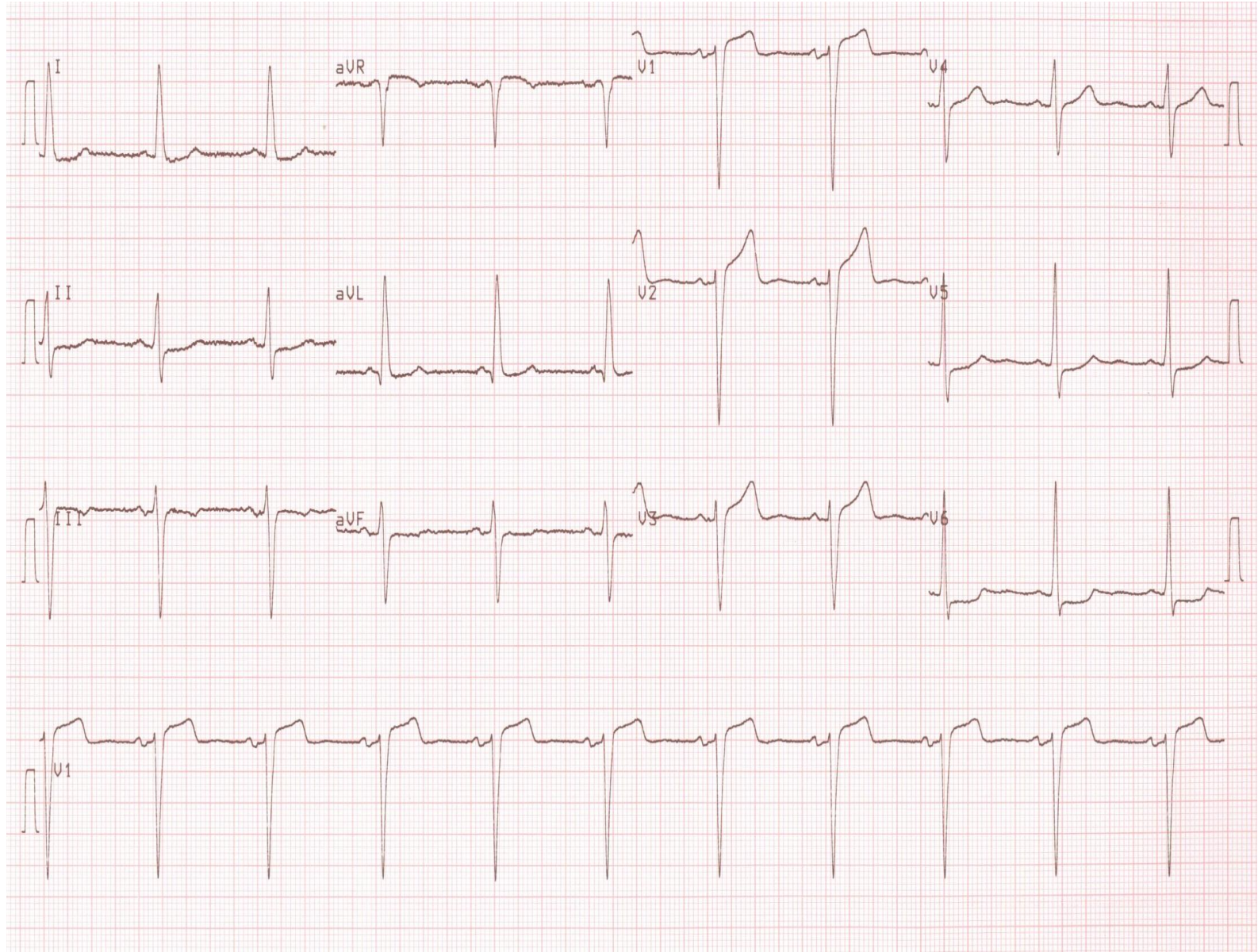
-HTN

-Previous smoker

# CLINICAL CASE PRESENTATION

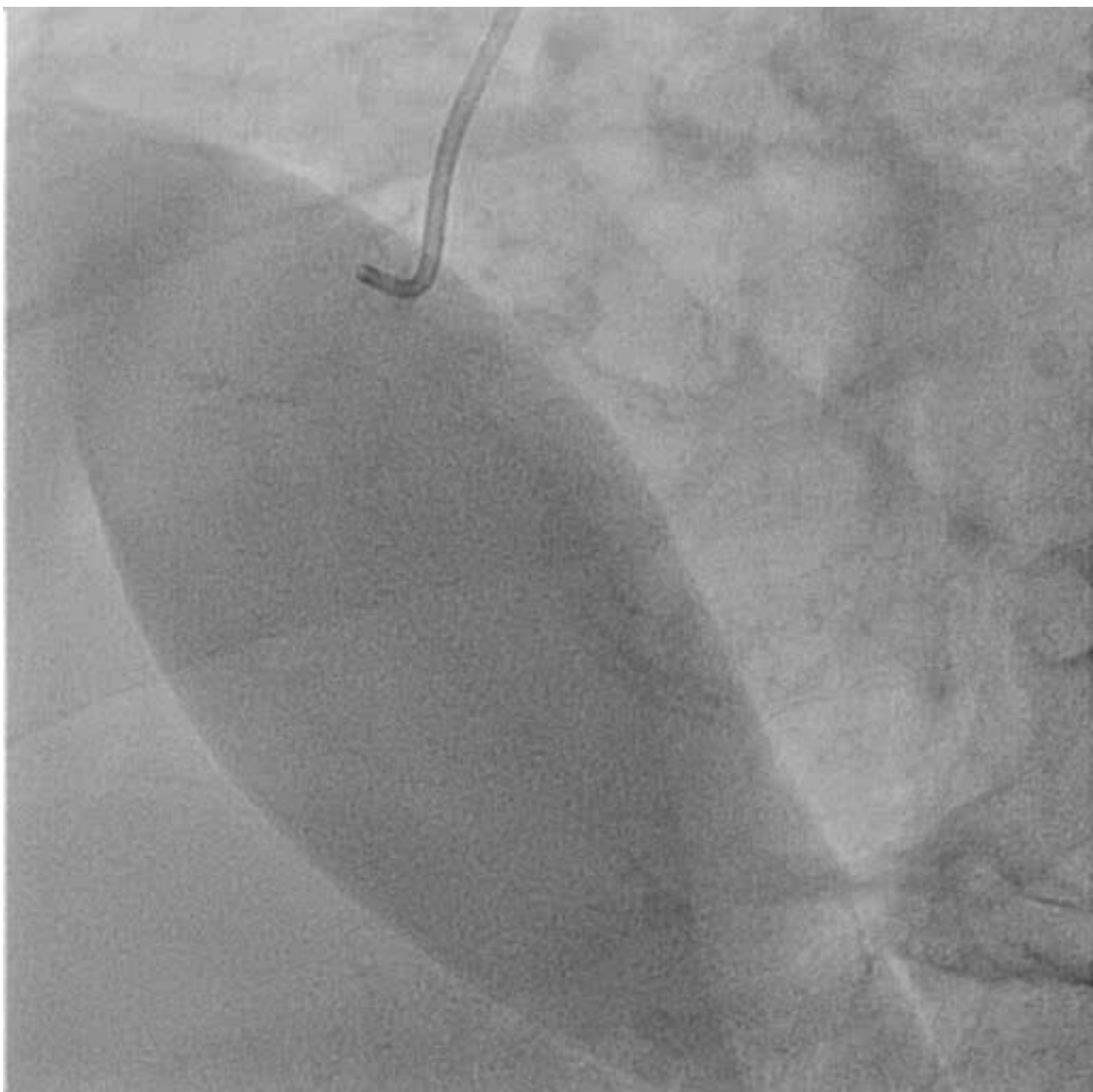
For chest pain both during effort and at rest a CCT scan was advised

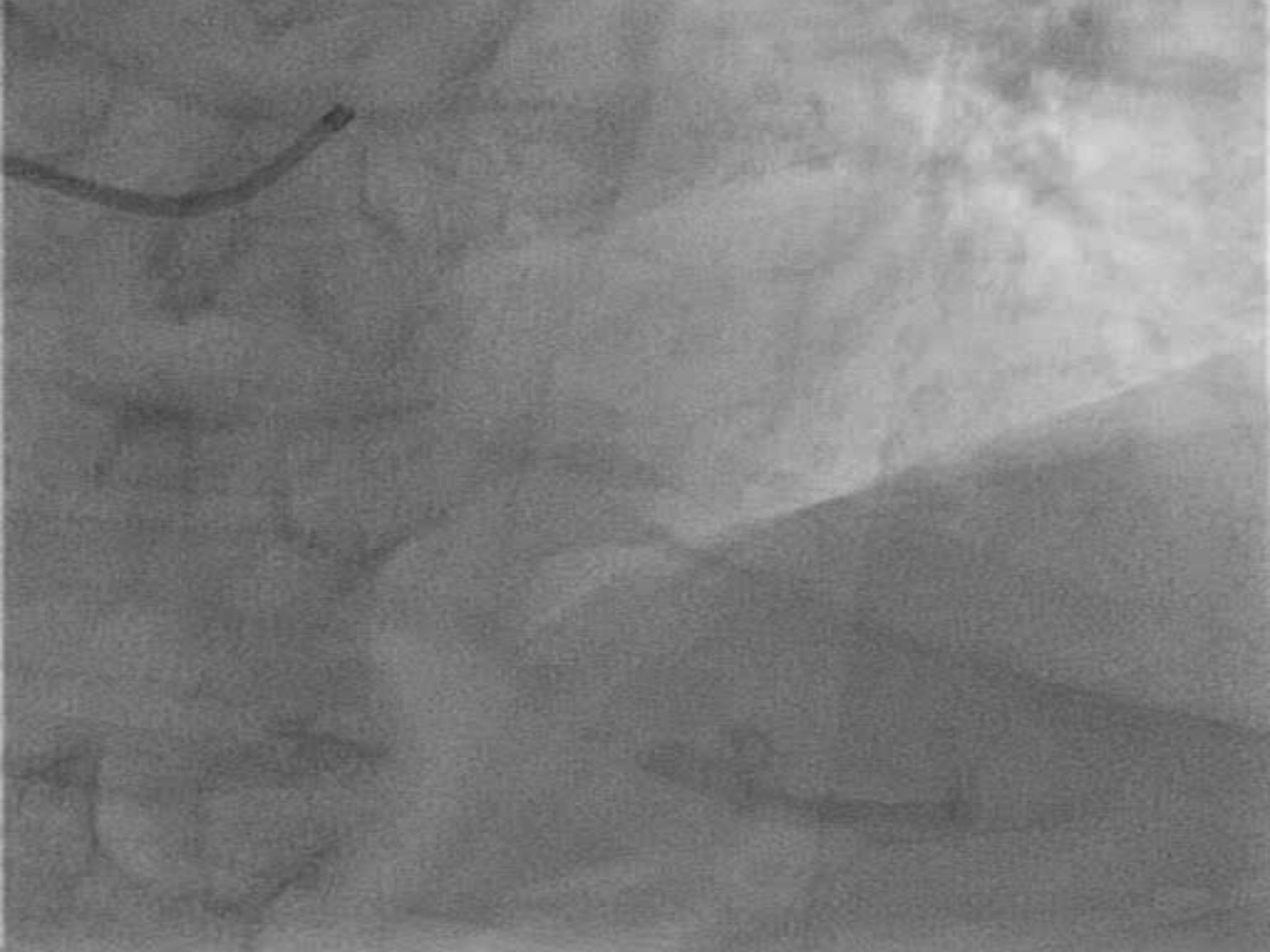
# CLINICAL CASE PRESENTATION



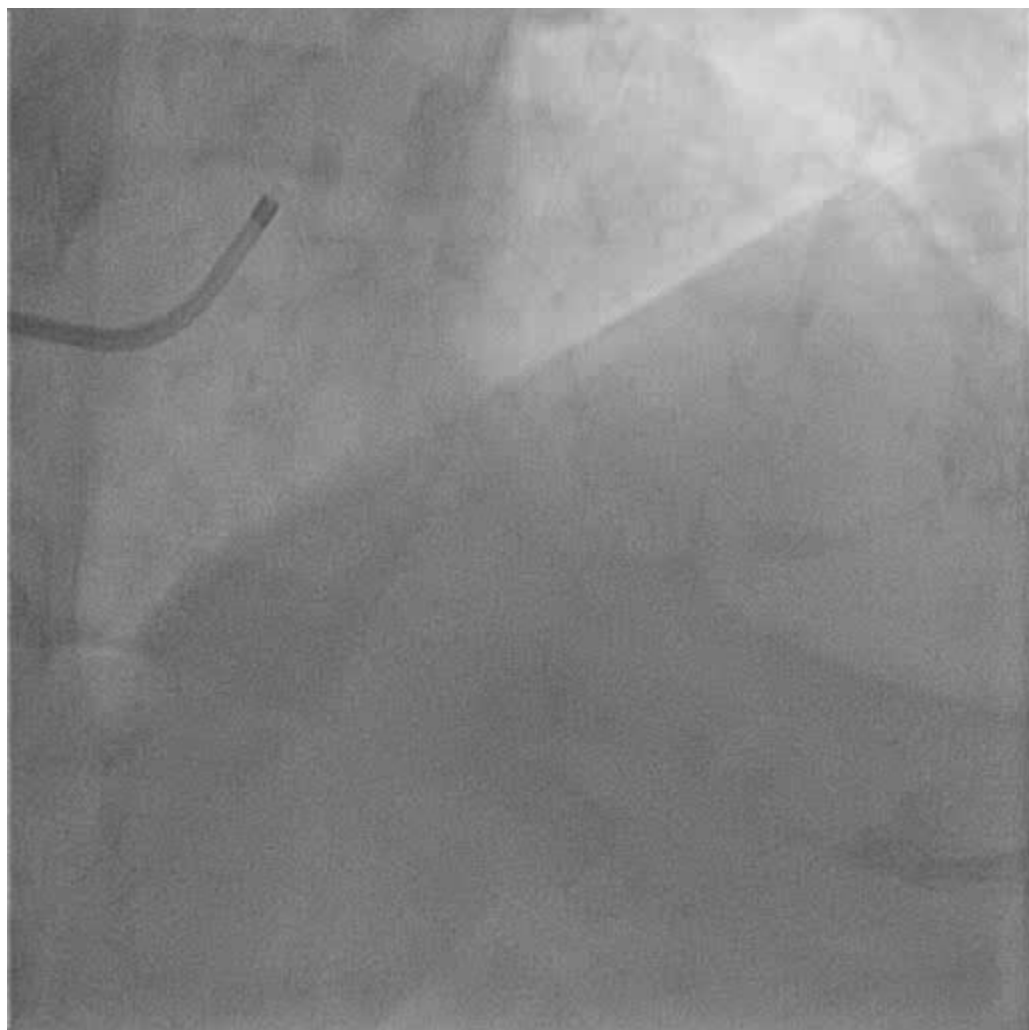
# CCT report

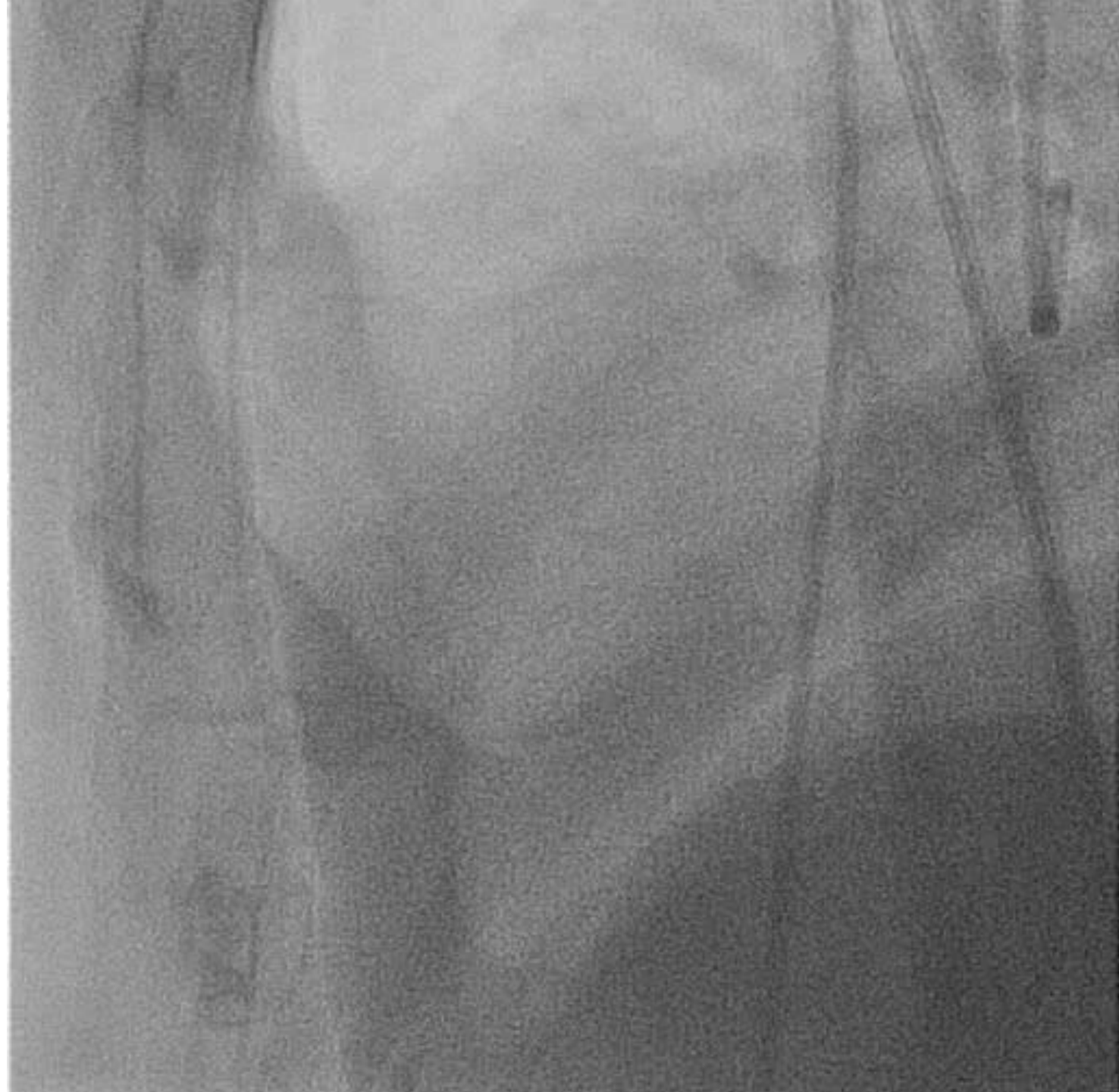“diffuse calcification of LAD not allowing detection of possible stenosis”

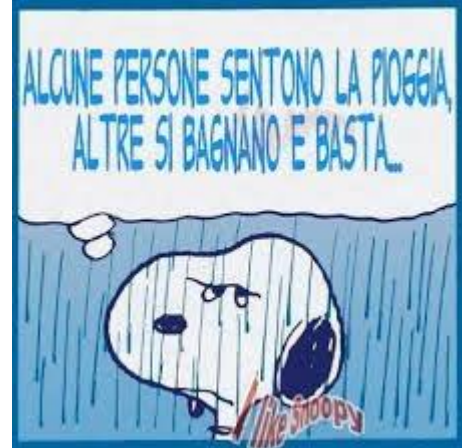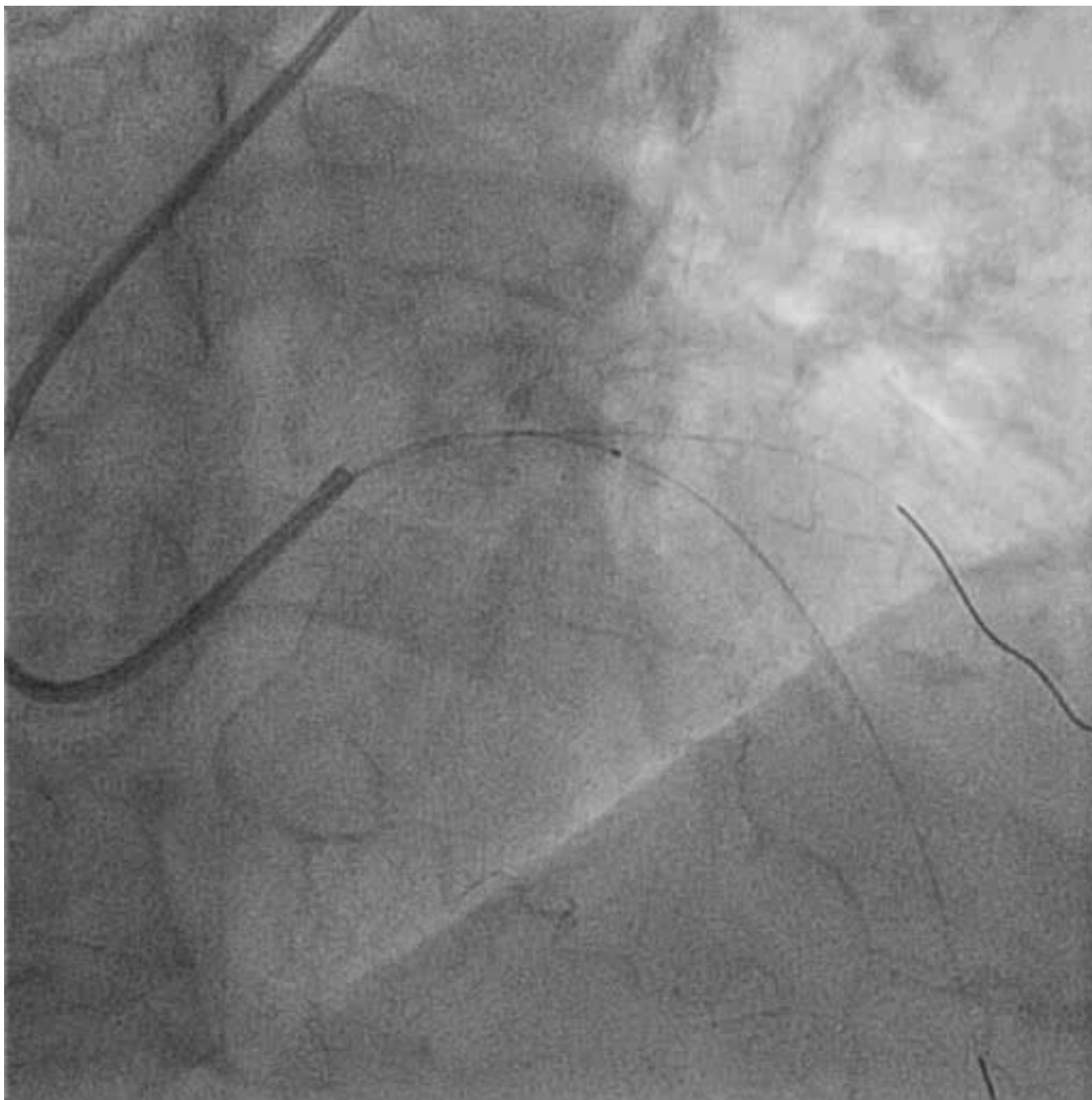


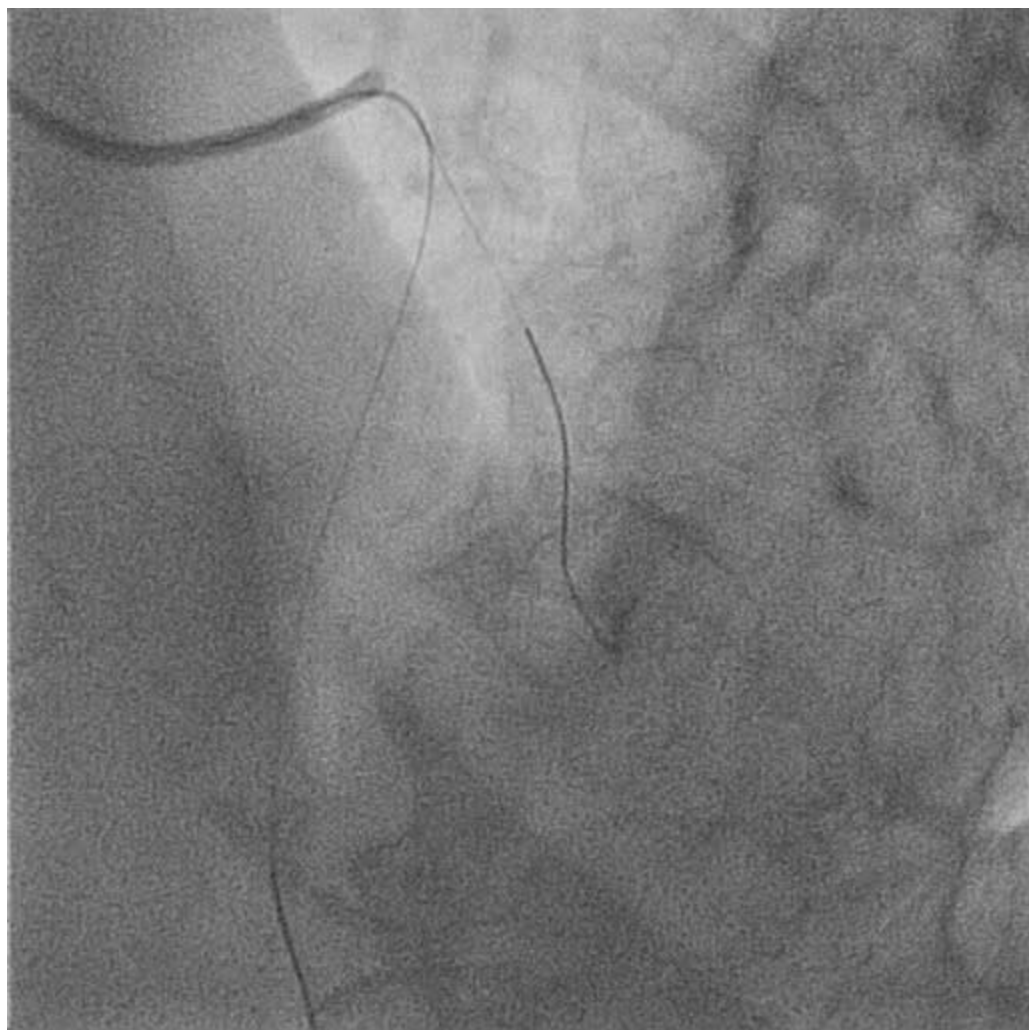


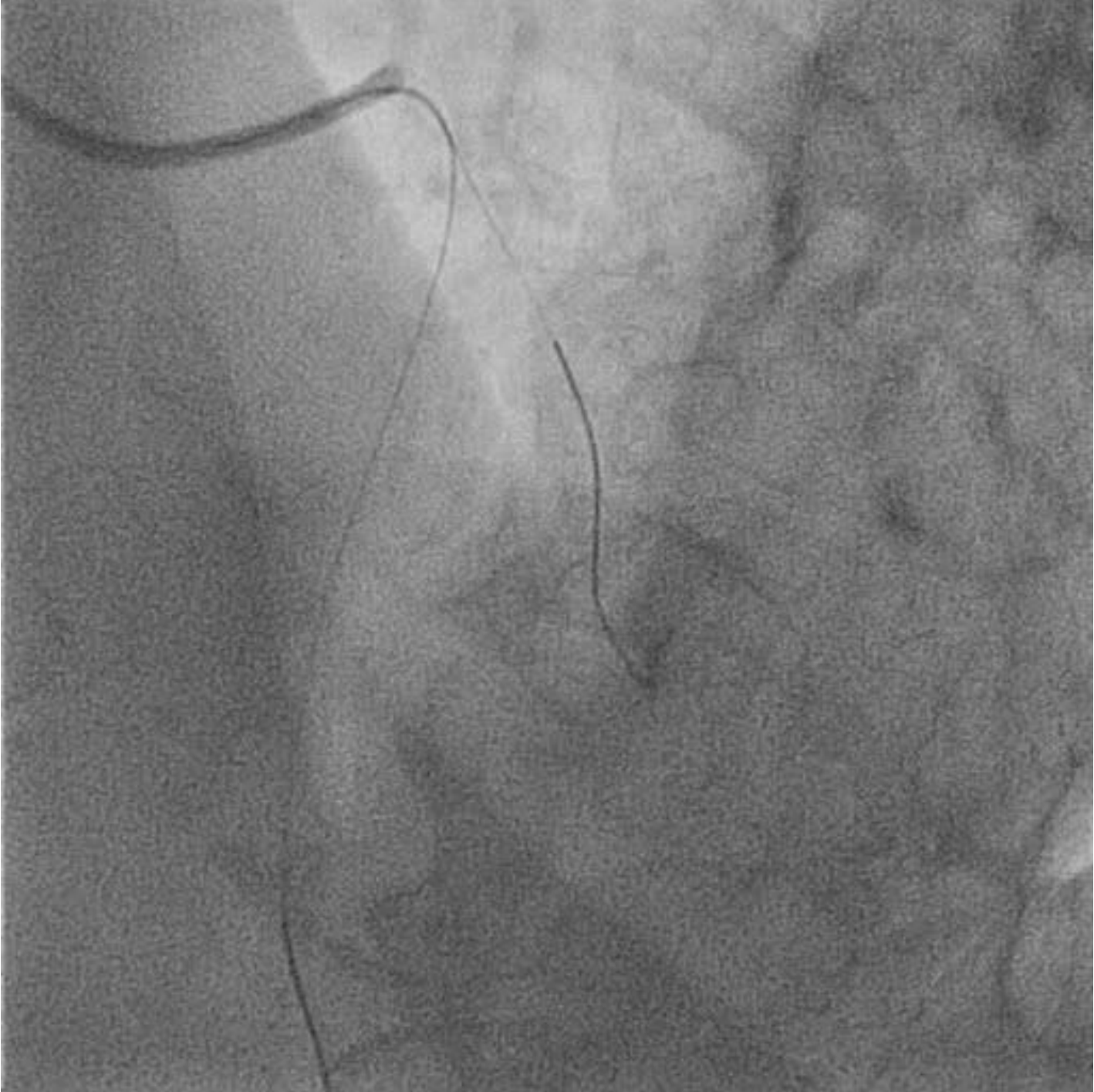






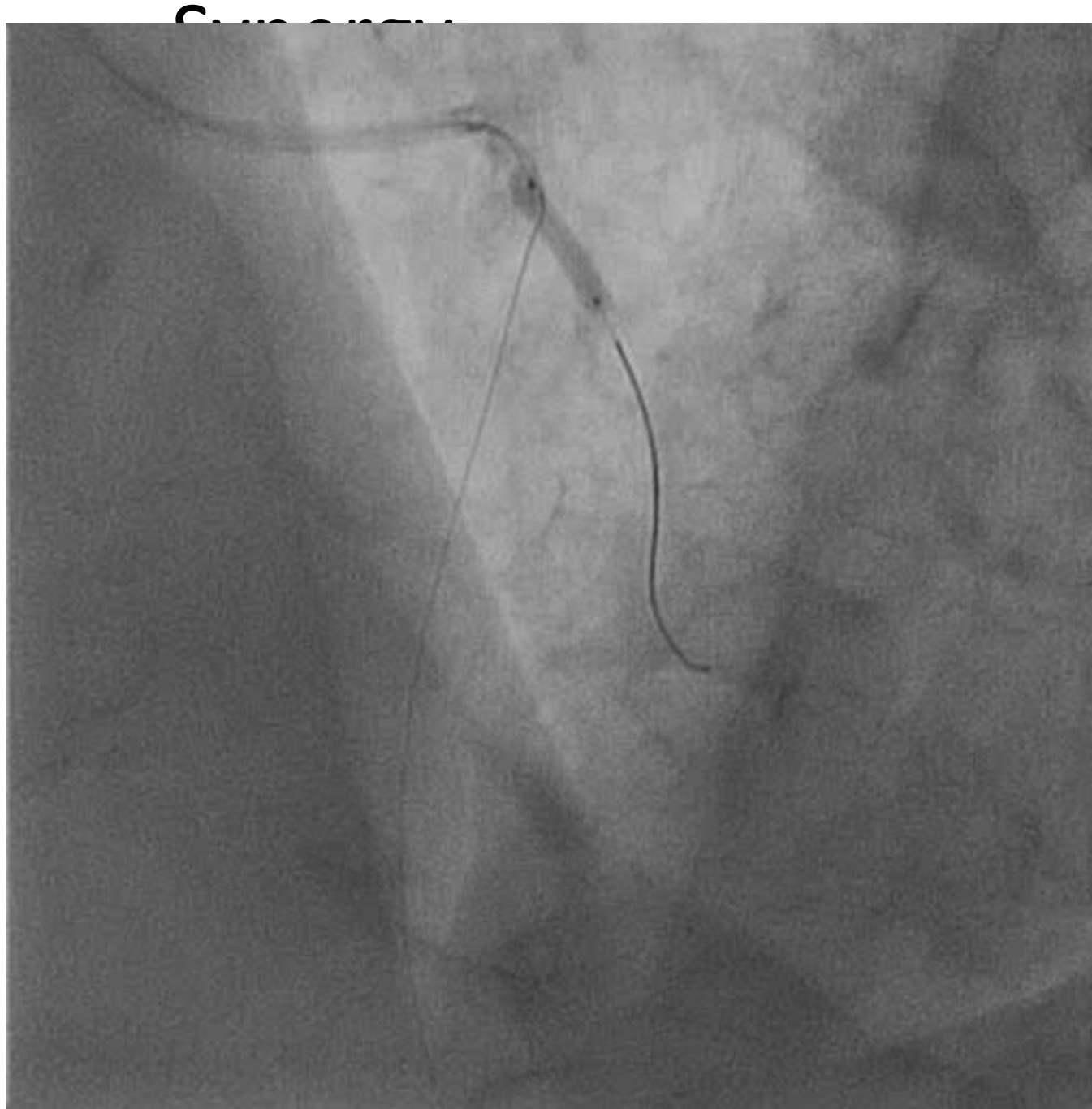


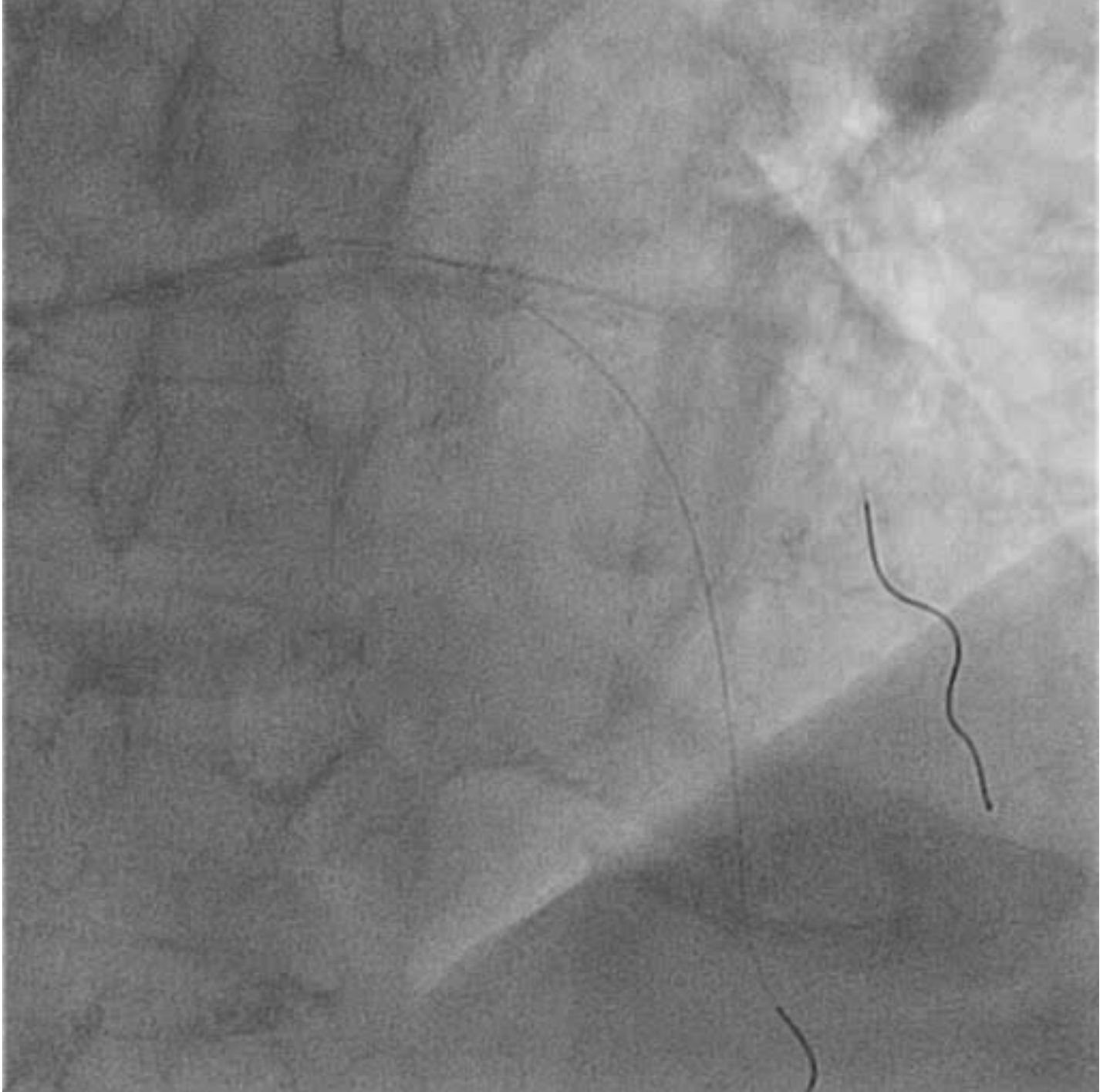


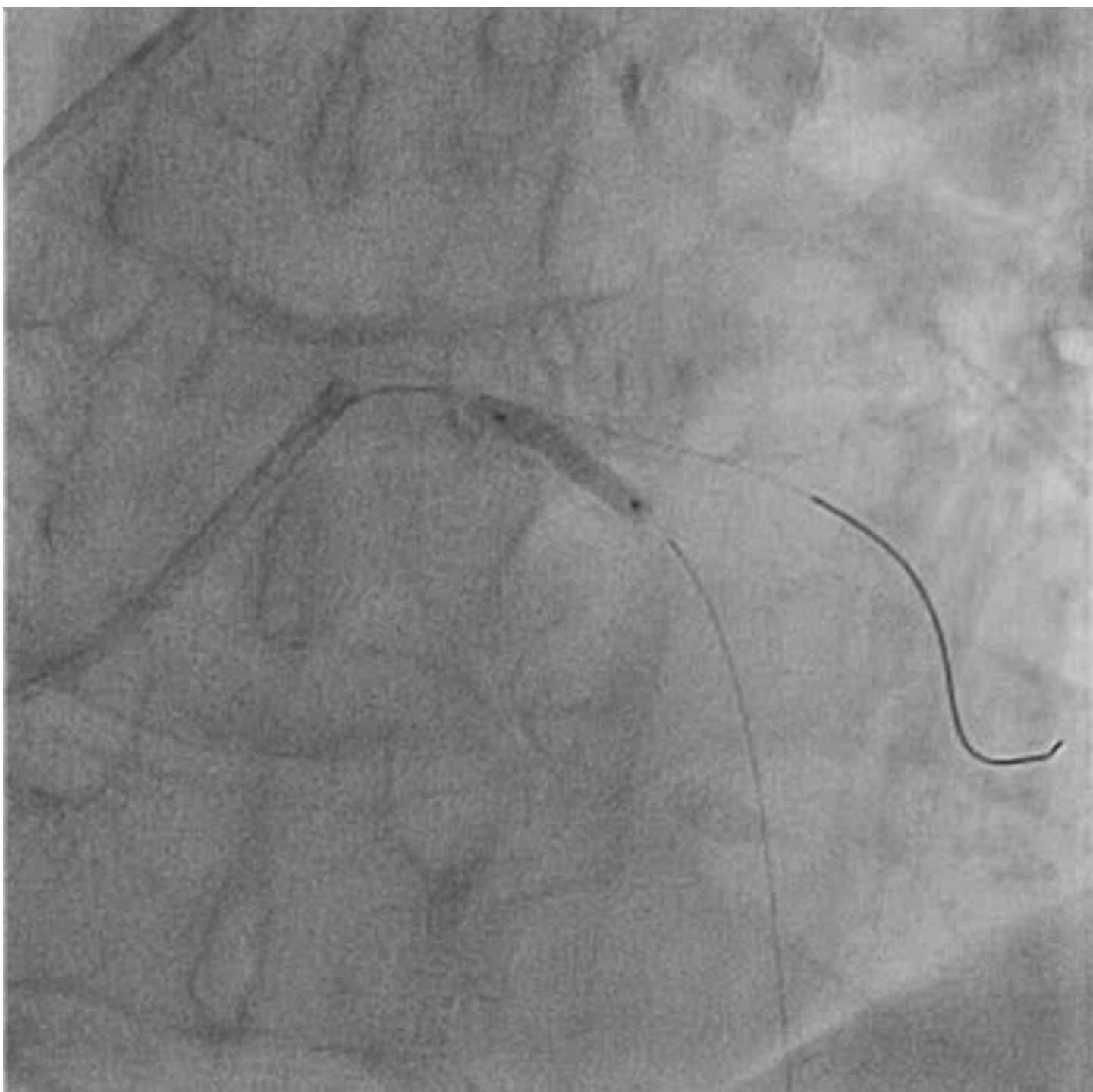




Synergy  
3.0x16

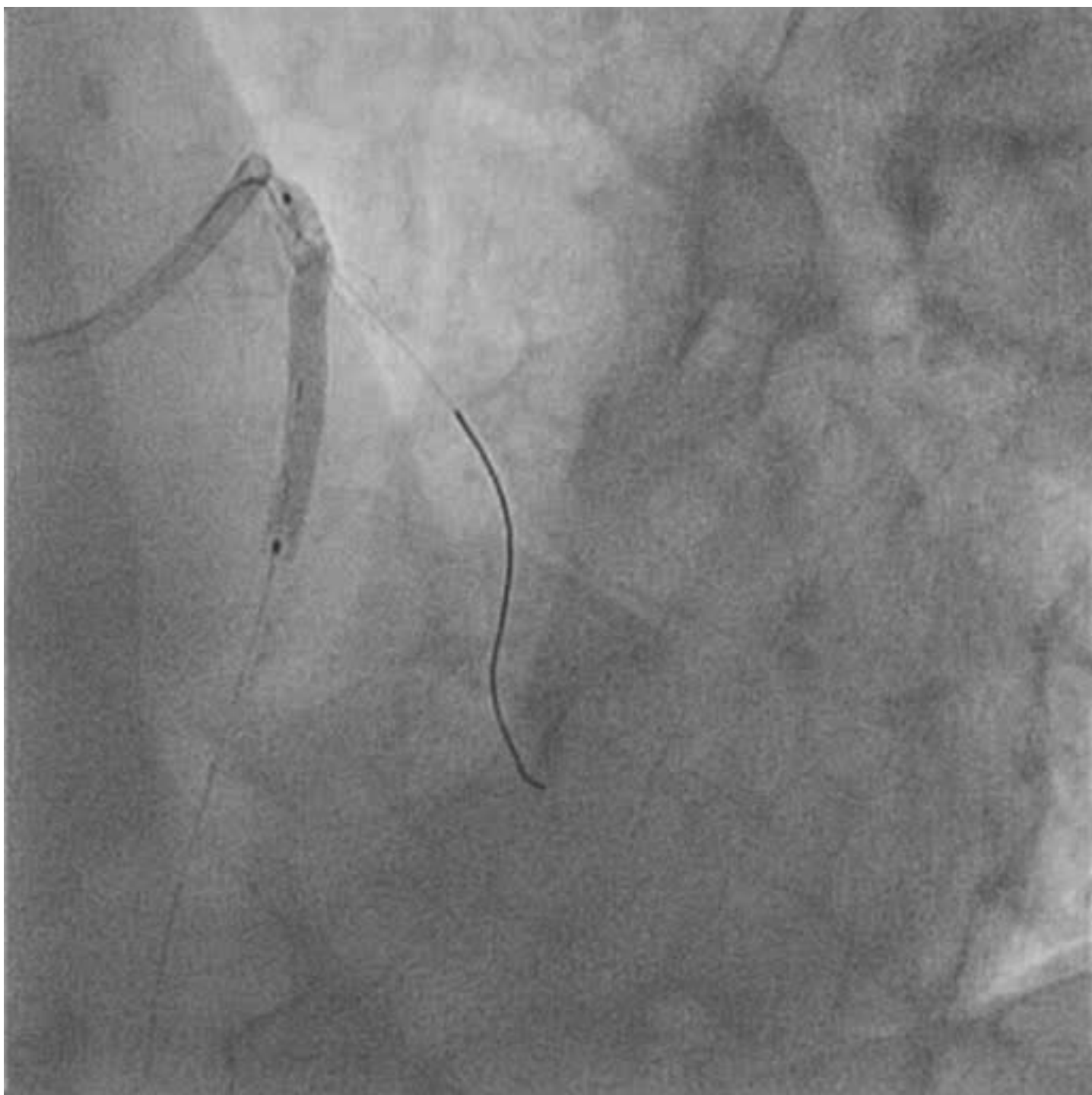


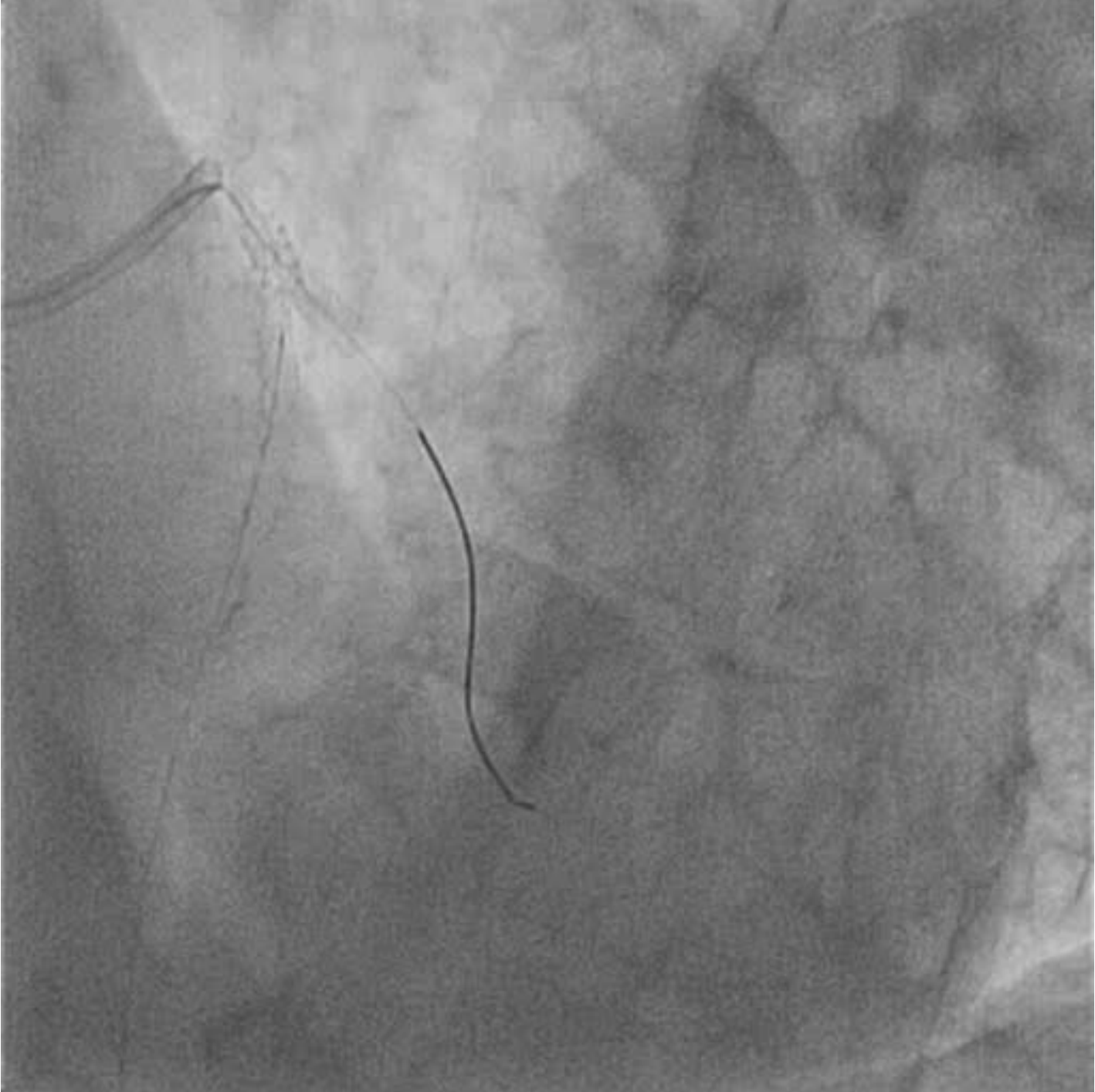


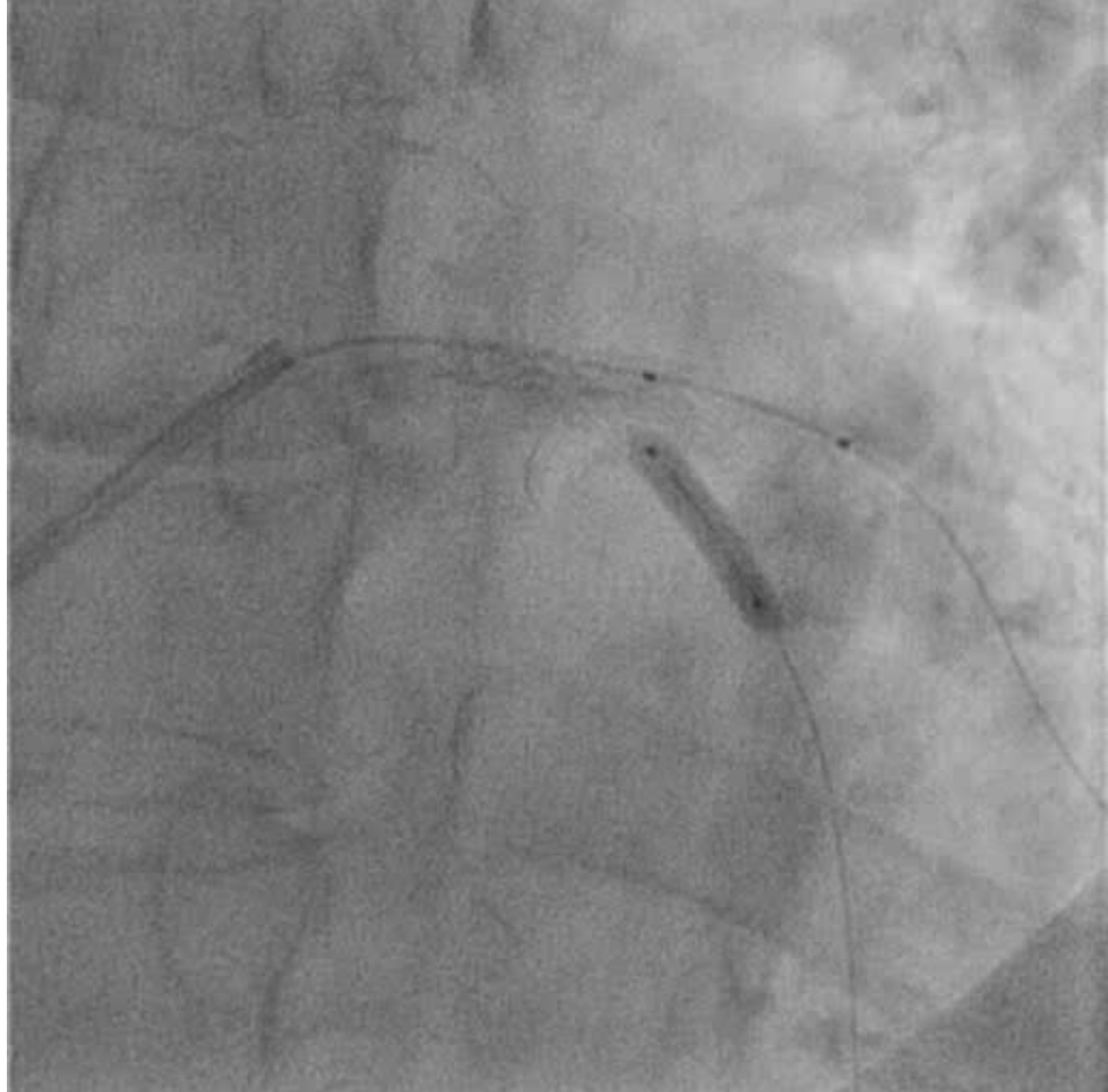


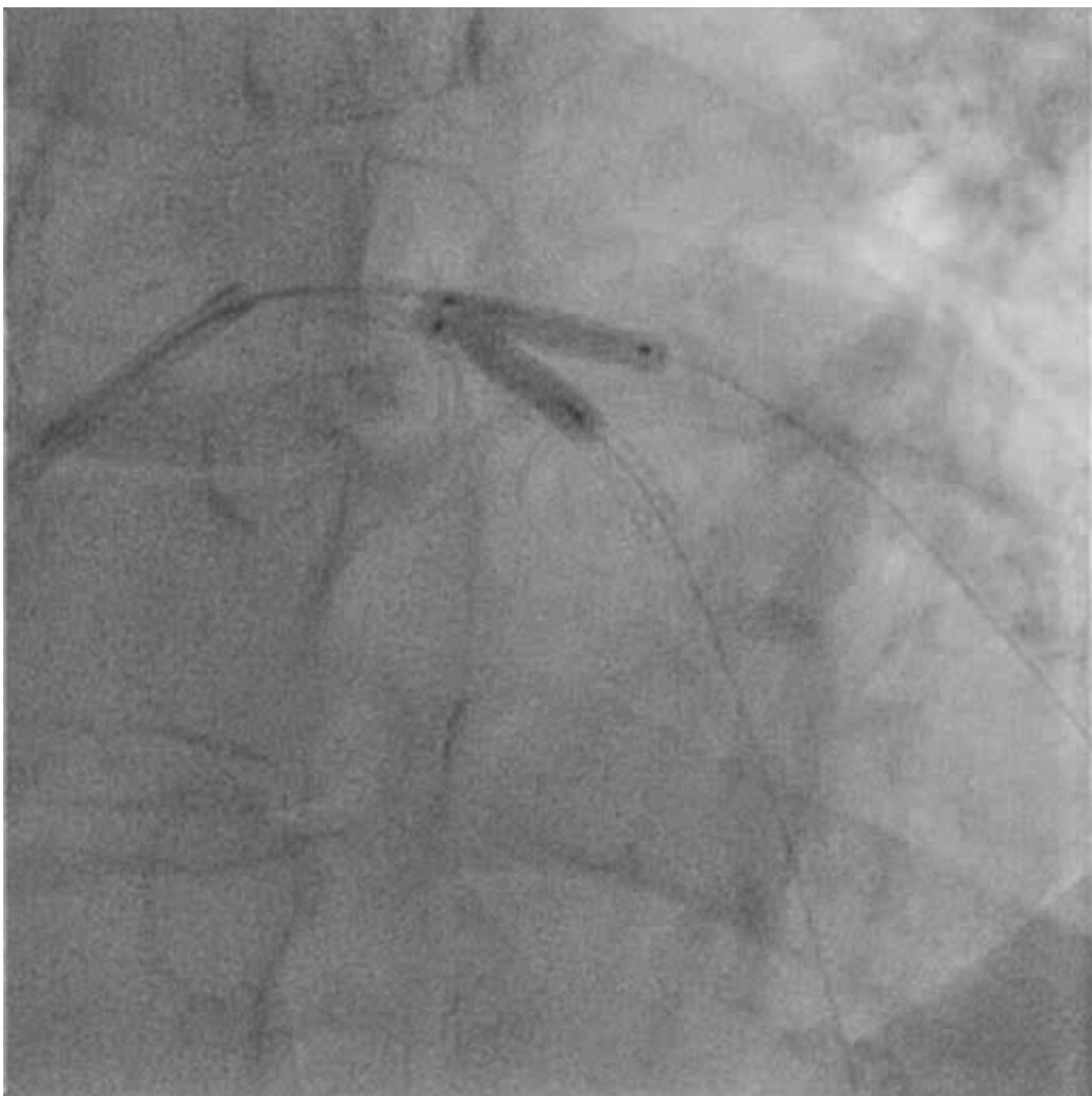


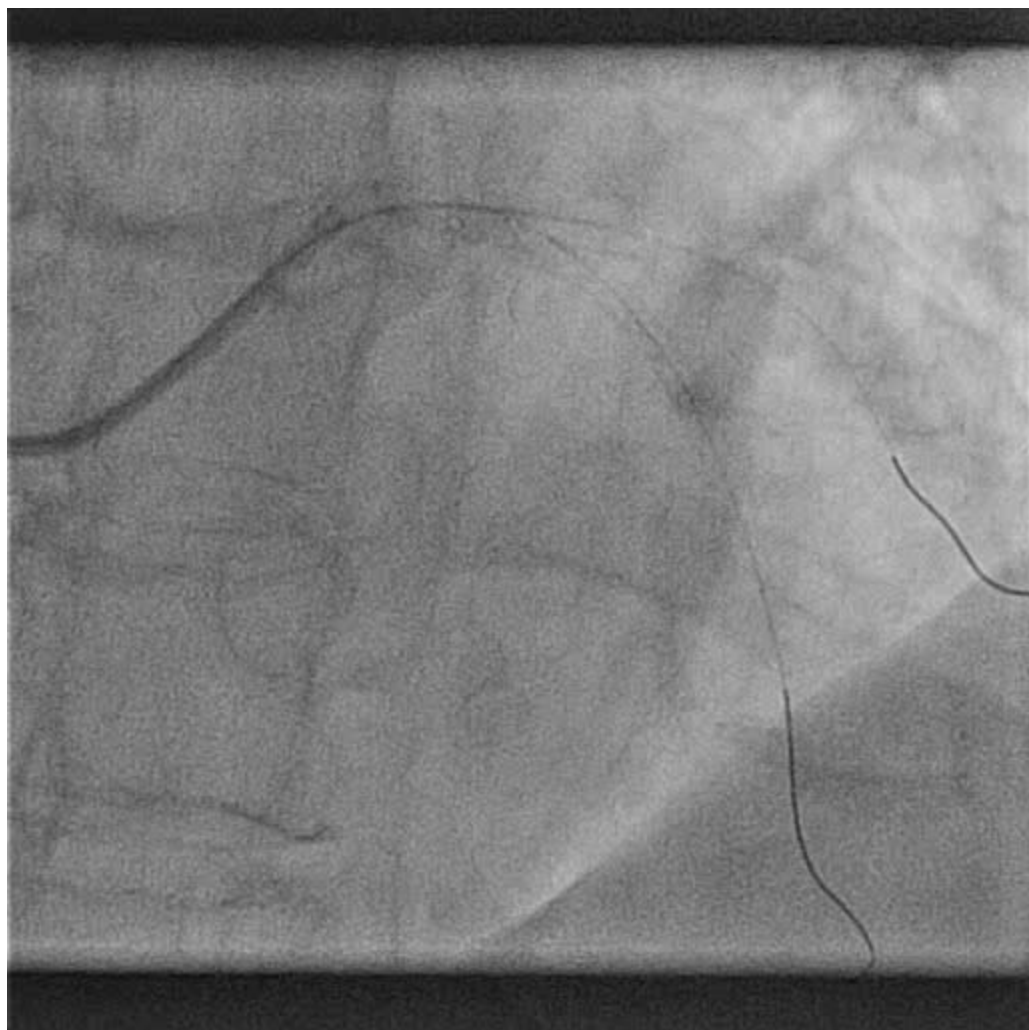
Synergy  
3.0x28

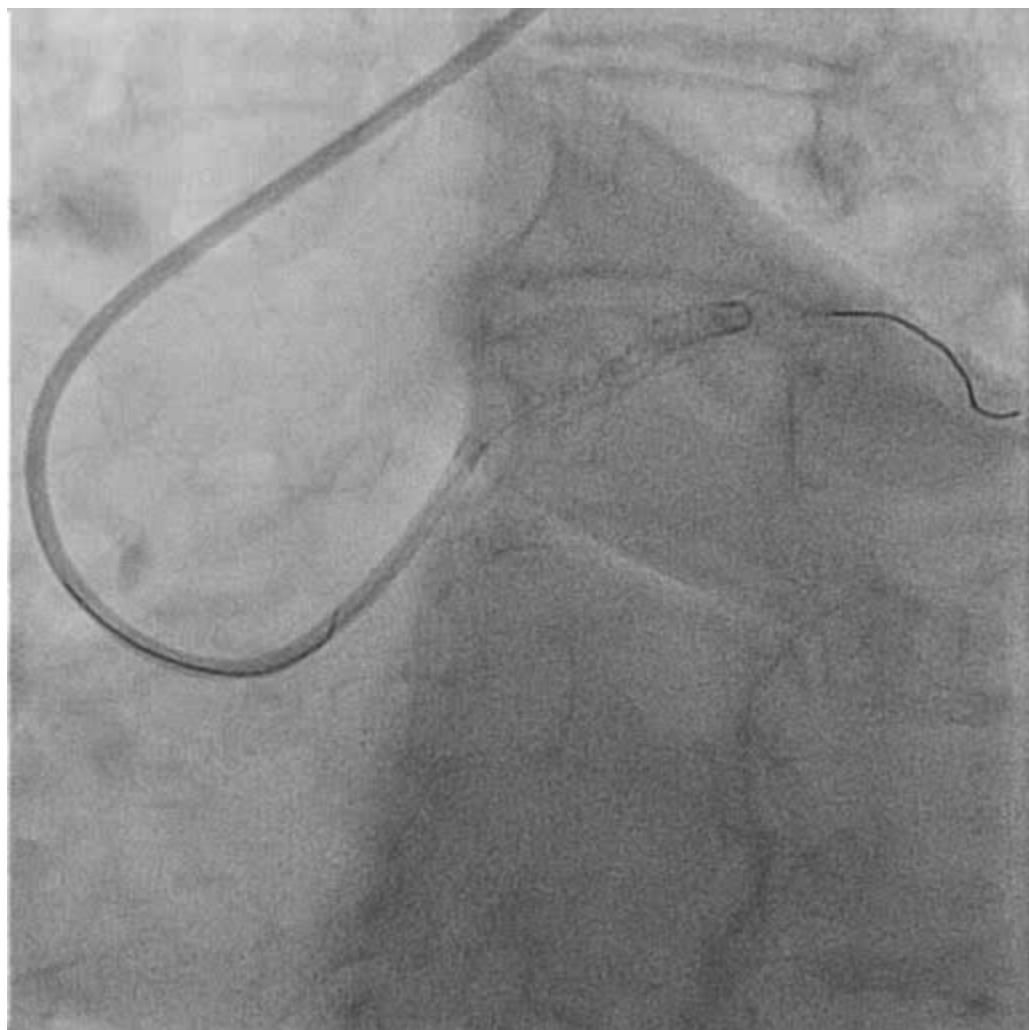

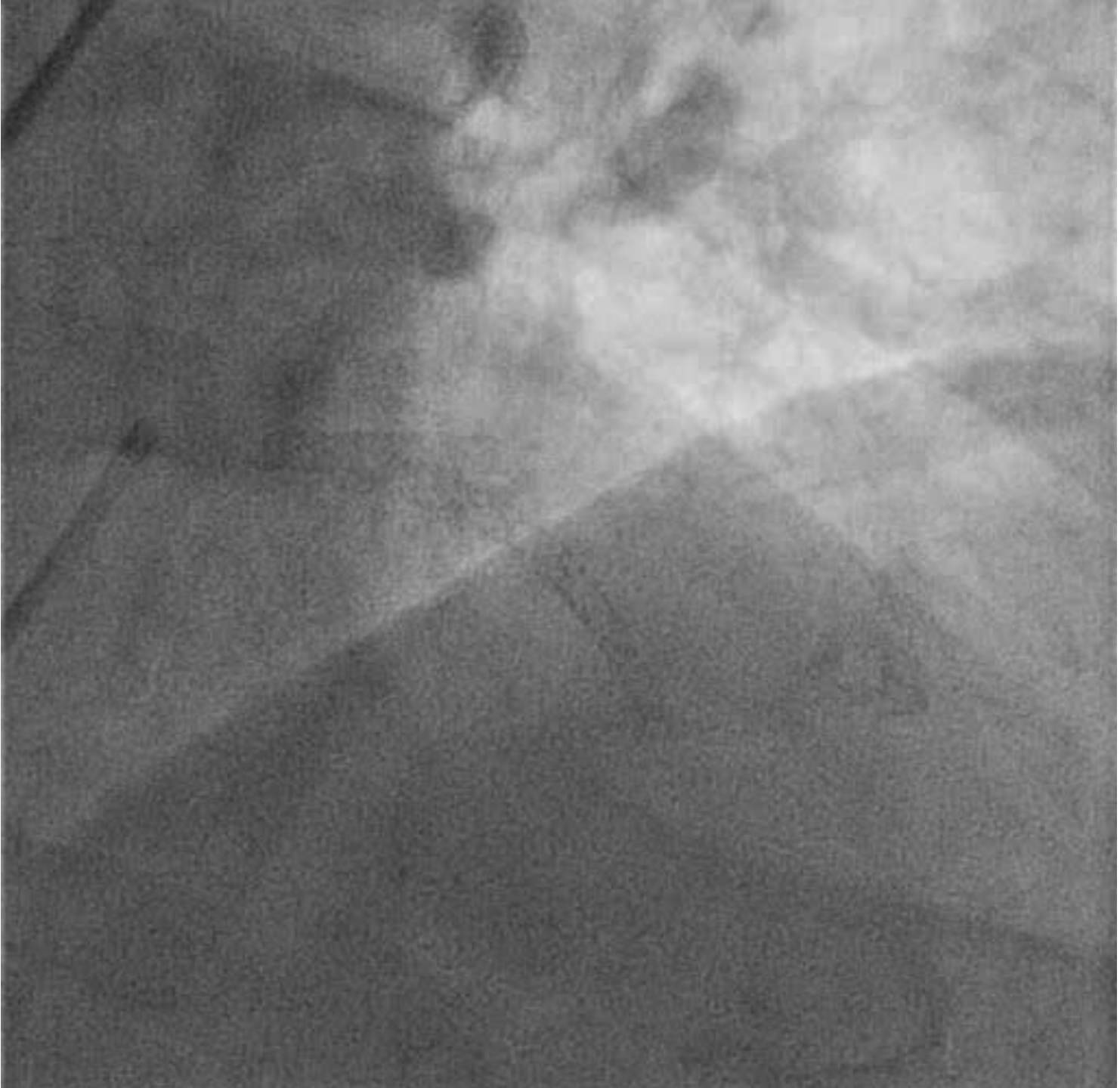


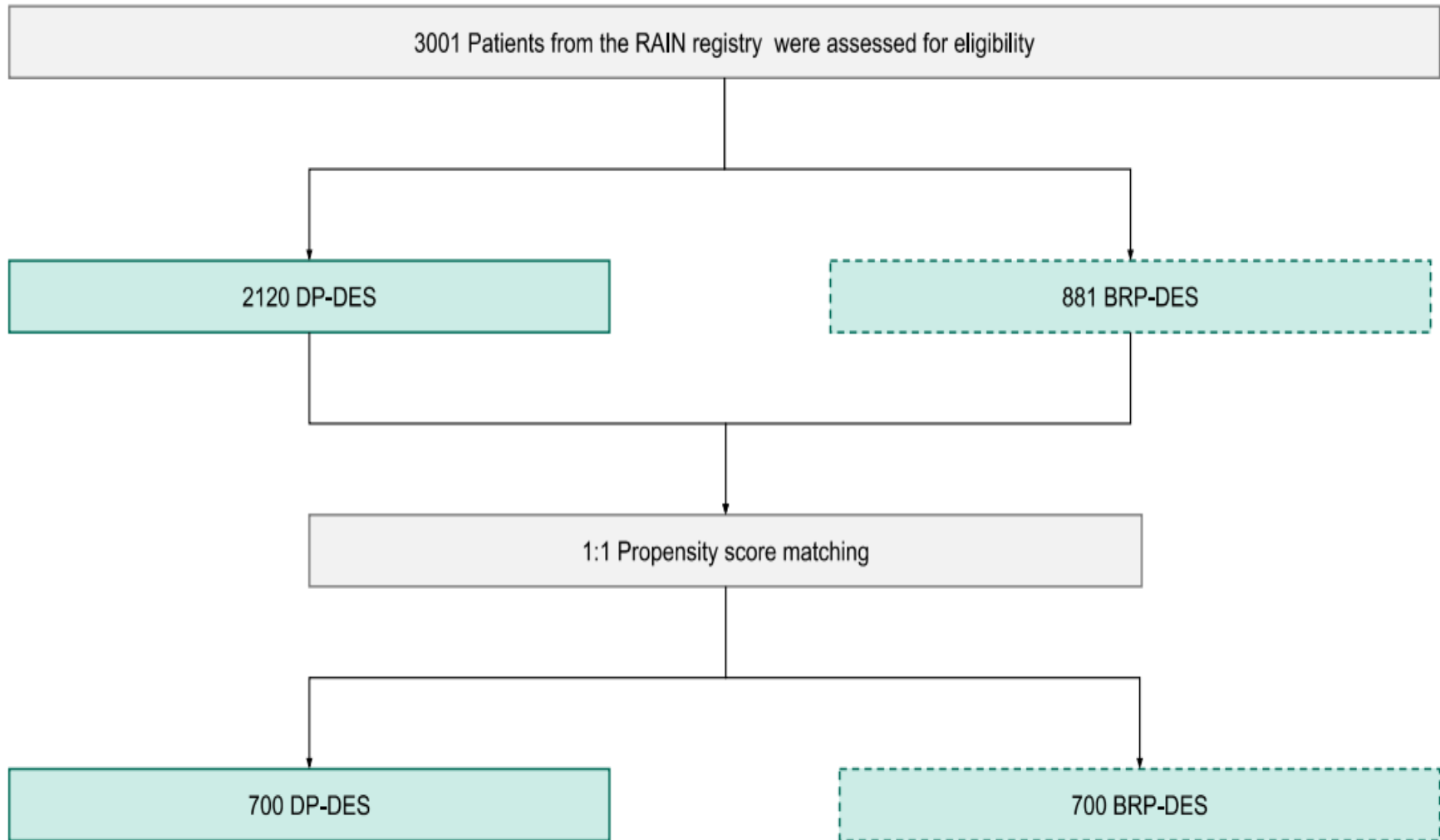




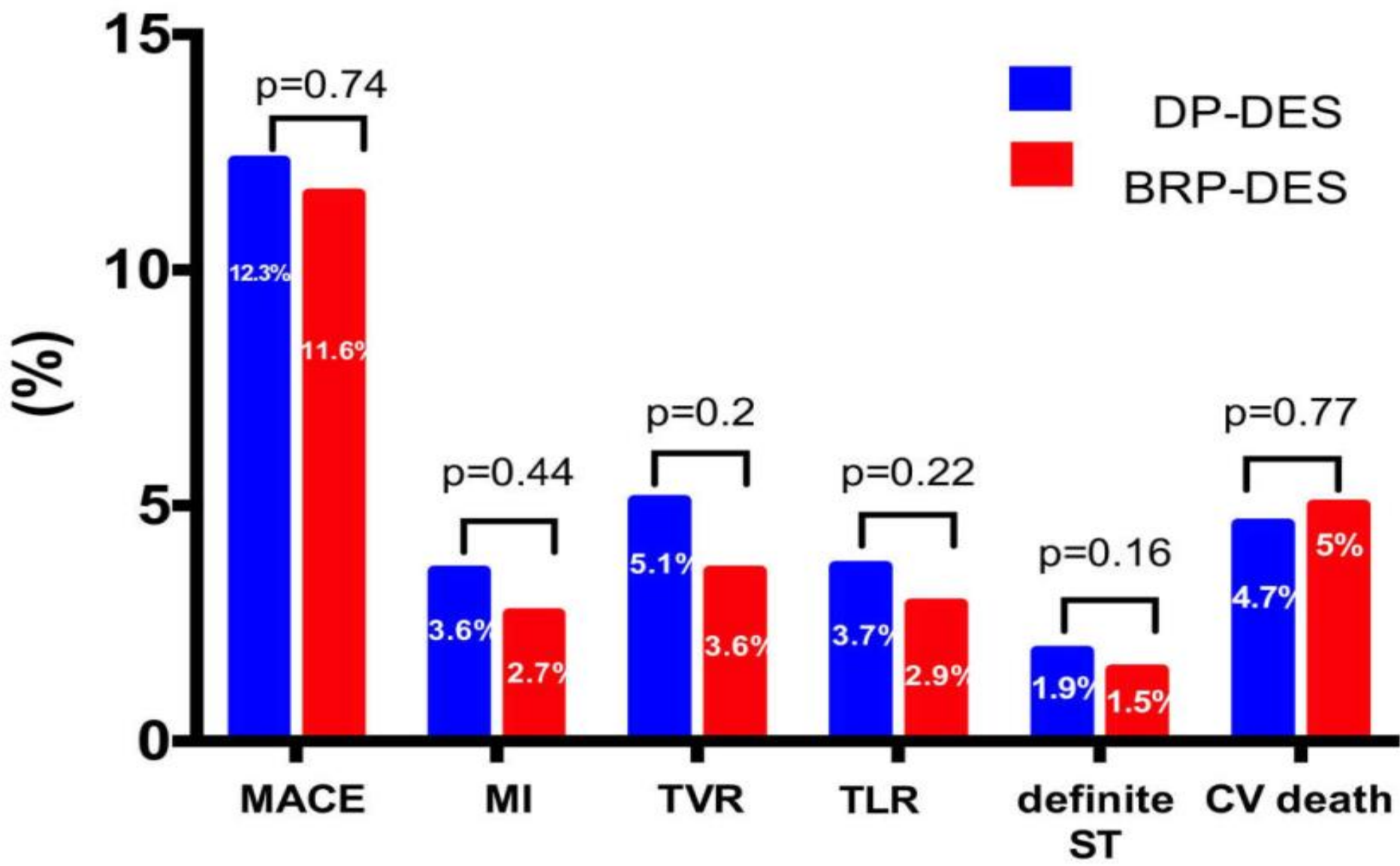




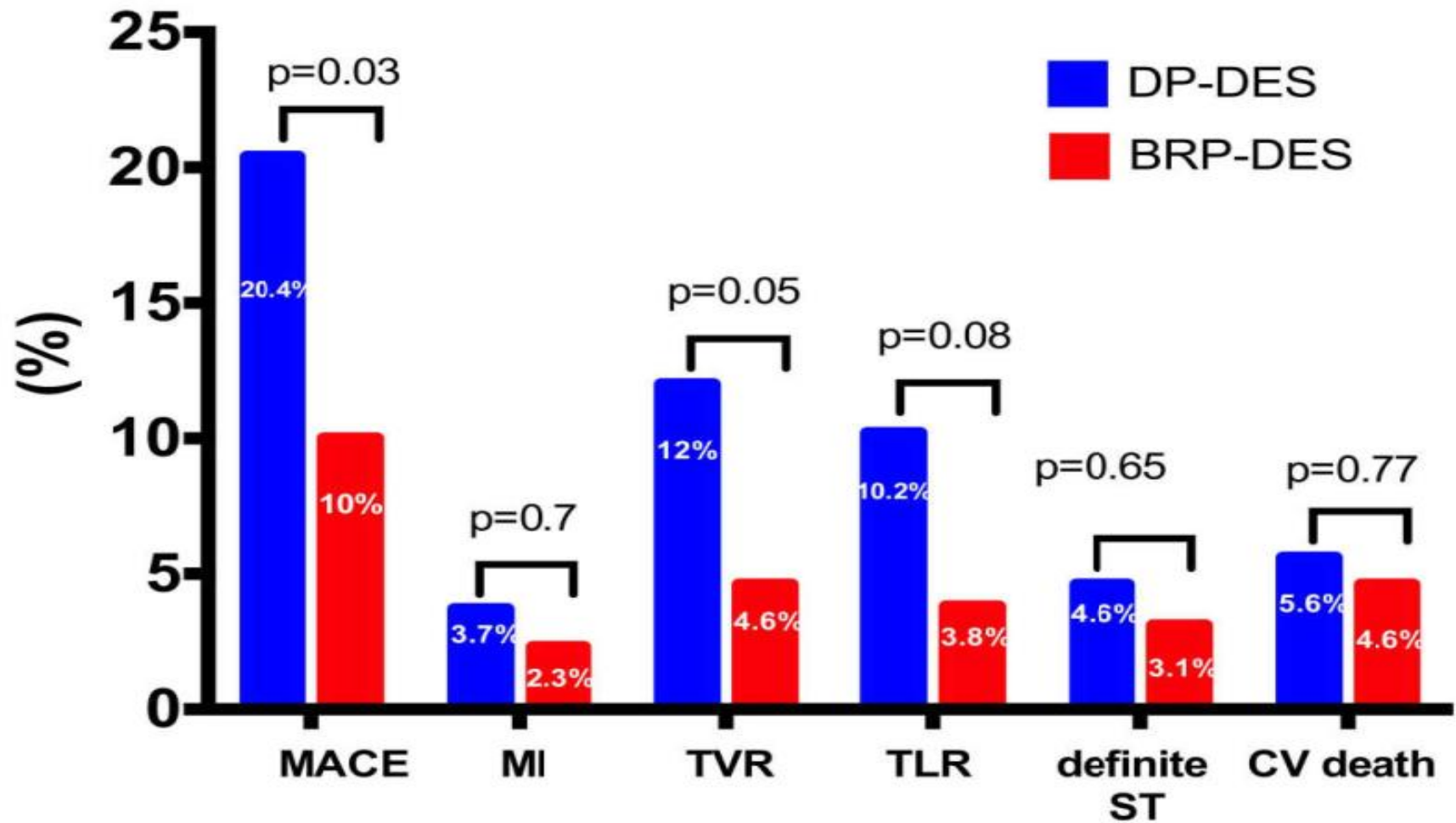








# Outcomes in patients treated with 2 stent technique



THANKS FOR THE ATTENTION

